

# 13

## Nasal Cavity and Paranasal Sinus Carcinoma

---

### I. GROSS DESCRIPTION

#### **Specimen**

- fine needle aspirate/biopsy/resection, e.g. rhinectomy, maxillectomy, ethmoidectomy, craniofacial resection/neck dissection.
- weight (g) and size (cm), number of fragments.

Clinical presentation is with nasal obstruction, rhinorrhoea, epistaxis or facial pain. Investigation is by endonasal endoscopy with biopsy. Plain X-ray, CT and MRI scan can demonstrate and stage a soft tissue mass and any bone destruction. Tumour can be removed piece-meal by fibre-optic endoscopic (sinus) surgery (FE(S)S) or more formal resection used. Nasal septal lesions are excised via a lateral rhinotomy. Medial maxillectomy is the commonest procedure for low-grade tumours of the lateral nasal cavity, or maxillary, ethmoid and frontal sinuses, e.g. transitional papilloma or olfactory neuroblastoma. Craniofacial resection is for aggressive tumours or those of the frontal or ethmoid sinus that extend into the anterior cranial fossa. Orbital exenteration may be required if there is involvement of its bony wall. Neck dissection is carried out when there are proven metastases. These are complex specimens and they require careful marking by and liaison with the surgeon.

#### **Tumour**

##### *Site*

- nasal cavity, maxillary sinus, ethmoid sinus, sphenoid/frontal sinuses.
- maxillary and ethmoid sinuses are the commonest tumour sites.
- mucosal/osseous/extrinsic.

##### *Size*

- length × width × depth (cm) or maximum dimension (cm).

##### *Appearance*

- exophytic/papillary/mucoid/sclerotic/chondroid/osseous.

##### *Edge*

- circumscribed/irregular.

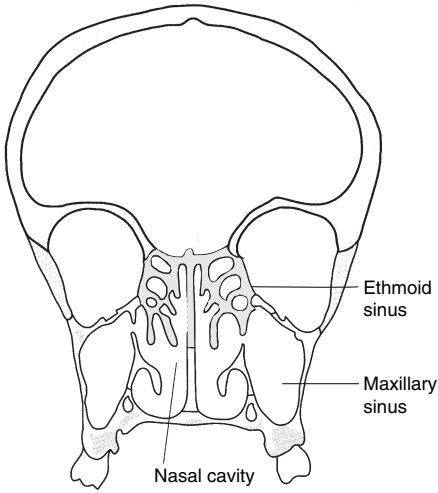


FIGURE 13.1. Paranasal sinuses. 

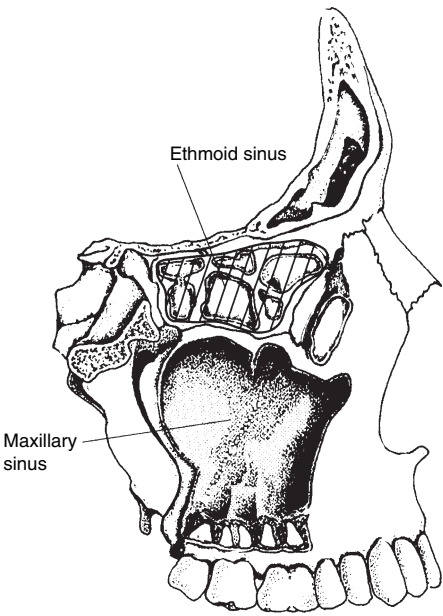


FIGURE 13.2. Paranasal sinuses. 