

7

Anal Canal Carcinoma (with comments on pelvic exenteration)

I. GROSS DESCRIPTION

Specimen

- anal tumours present as a mass or feeling of fullness. For therapeutic reasons clear clinicopathological distinctions must be made
 - rectal type adenocarcinoma arising from the distal rectum or the colorectal zone of the upper anal canal can spread downwards and present as an anal tumour. Treatment is surgical (APR) \pm neoadjuvant therapy (see Chapter 5).
 - anal canal squamous carcinoma can spread upwards or downwards presenting as low rectal or perianal/anal margin tumour, respectively. Treatment is primarily radio-/chemotherapy and not surgical.
 - perianal/anal margin squamous carcinoma can be confined to the skin or spread to involve the distal anus. Treatment is local surgical excision for the former and more radical surgery or radiotherapy alone or in combination for the latter.
 - anal canal adenocarcinoma, malignant melanoma or sarcoma are surgically resected.
 - investigation of anal tumours is by anoproctoscopy and biopsy with endoanal ultrasound, MRI and CT scans to stage biopsy-proven disease.
- biopsy/resection (local or abdominoperineal).
- weight (g) and size/length (cm), number of fragments.

Tumour

Site

- mucous membrane/muscularis/extramural.
- low rectal/anal canal/perianal margin or skin.
- anatomy:
 1. upper zone: colorectal mucosa
 2. transitional/cloacal zone: stratified cuboidal epithelium with surface umbrella cells + anal glands in submucosa
_____ dentate (pectinate) line _____
 3. lower zone: stratified squamous epithelium continuous with appendage bearing perianal skin.

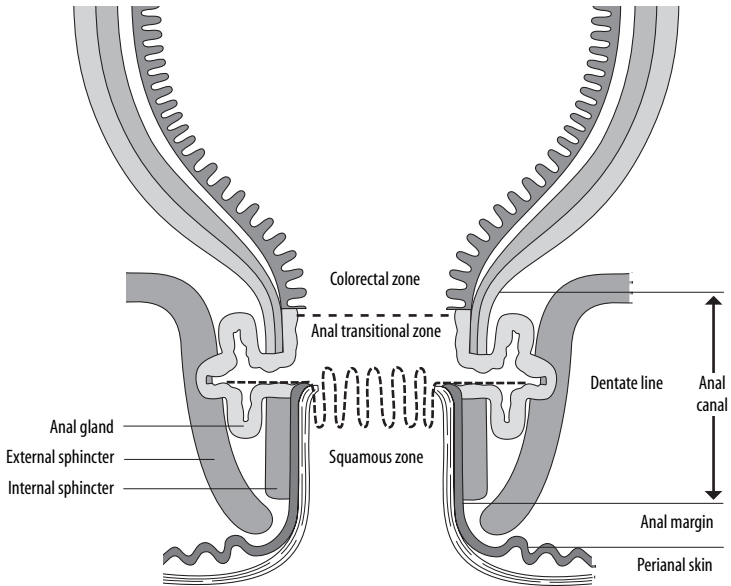


FIGURE 7.1. The anatomy of the anal canal. (Williams GR, Talbot IC. Anal carcinoma: a histological review. *Histopathology* 1994;25:507–516 Reproduced with permission from Blackwell Publishing Ltd)

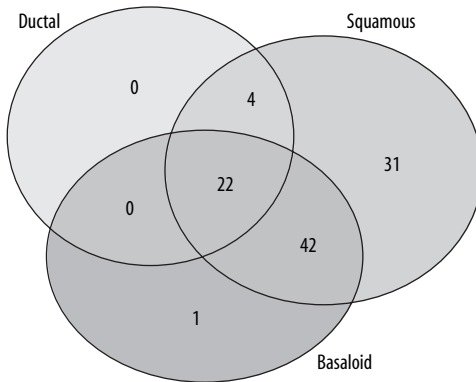


FIGURE 7.2. Anal canal carcinoma: overlap in histological subtypes. (Williams GR, Talbot IC. Anal carcinoma: a histological review. *Histopathology* 1994;25:507–516 Reproduced with permission from Blackwell Publishing Ltd)